

Fabrication of Light Weight Titanium Hollow Bulb Obturator in A Maxillectomy Patient– A Clinical Report

Dr. B. Devi Parameswari, M.D.S¹., Dr. S. Manu Partheban²,
Dr. H. Annapoorni, M.D.S³.,

¹Associate professor, Department of Prosthodontics, Meenakshi Ammal Dental College and Hospital,

²PG student, Department of Prosthodontics, Meenakshi Ammal Dental College and Hospital,

³Professor and Head of the Department, Department of Prosthodontics, meenakshi ammal dental college and hospital

Abstract: Replacement of the missing teeth and associated structures in a maxillectomy patient is a challenging task for the maxillofacial prosthodontist. This article discusses about a clinical case of a maxillectomy patient, who is restored with a light weight titanium hollow bulb obturator. This prosthesis improves the comfort and health of the patient.

Keywords: maxillectomy, titanium, hollow bulb obturator,

I. Introduction

Patients with palatal defects suffer functional difficulty and esthetic deformity. After the surgical resection, restoring the physical and mental well-being of the patient is of paramount importance. Maxillofacial prosthodontist replaces the lost tissue by obturator, which not only restores function but also reclaims the patients' well-being¹.

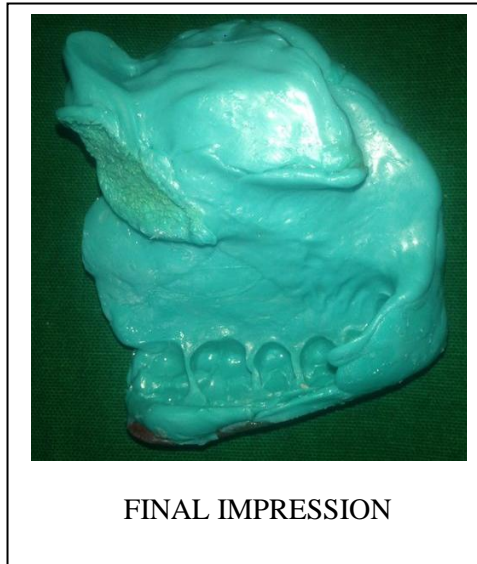
Obturator is a prosthesis to close a palatal defect in a dentulous or edentulous mouth. The degree of extension into the defect varies depending upon the configuration of the defect, character of its lining tissue, and functional requirements for retention, support, and stabilization of the prosthesis. In large defects lacking palatal support, the obturator is aggressively extended vertically to engage the surgical defect and horizontally to the lateral aspect of the orbital floor, at the expense of its size and weight. Remaining structures are subjected to continuous stresses from such large, heavy obturator, jeopardizing the health of the tissues, and compromising patient function and comfort.

There are various methods to reduce the bulk of the prosthesis⁹. Restoring the maxillary defect with a titanium hollow bulb obturator², is one of the methods, which reduces the weight of the prosthesis, improves the comfort to the patient. In this article we are presenting a clinical case treated with a titanium hollow bulb obturator.


II. Case Report

A 45 year old male patient reported to the department of PROSTHODONTICS, MEENAKSHI AMMAL DENTAL COLLEGE AND HOSPITAL, for the replacement of existing two year old single piece acrylic obturator. Patient complains of escape of air at the posterior aspect of denture and displacement of denture due to its weight. On examination, Armany's class IV palatal defect involving left maxilla and part of right maxilla, crossing the midline was observed. Obturator reveals deficiency in the posterior margin, fluid leakage, decreased retention and fall of denture due to heavy solid bulb. Patient was assured about rehabilitation with comfortable, less weight and more retentive denture. Treatment was planned to construct a titanium hollow bulb obturator³.

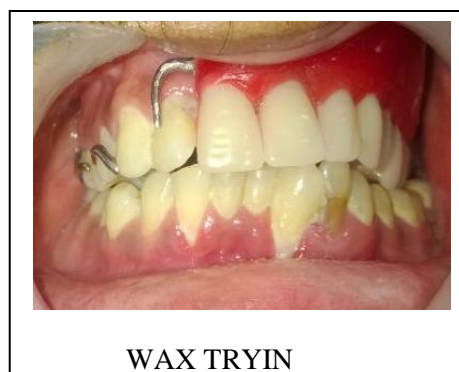
Mandibular alginate (ALGITEX, DPI, INDIA) impression was made. Impression of the maxillary defect was recorded with impression compound(Y-DENTS, MDM CORPORATION, INDIA). Positioning the impression compound in the defect, a pickup impression is made with alginate using stock tray. Primary cast was poured with type 3 gypsum (ULTRASTONE, KALABHAI). A resin custom tray was fabricated in the primary cast after blocking the undercut; rest seats were prepared on the abutments. After the mouth preparation, an impression was made with (AQUASIL LV DENTSPLY) light body elastomeric impression material.

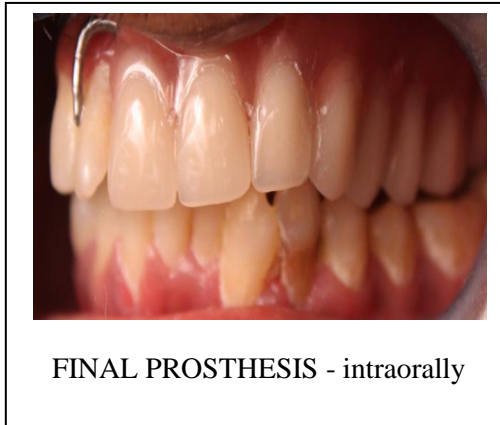
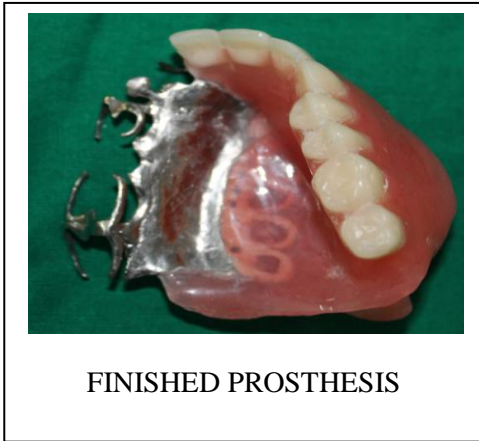


A secondary cast was poured with type 4 gypsum product. Shell wax pattern of 2mm thickness is fabricated in the defect portion. Wax pattern for the lid to close the defect is fabricated. Both hollow bulb shell portion and the lid portion is flaked, dewaxed and processed with heat cure denture base resin (DPI HEAT CURE, INDIA). The bulb and lid were trimmed and polished. After verification of fit of bulb and lid intra-orally, both were fused using chemically activated denture base resin. Titanium framework was made on the cast and metal try-in was verified.

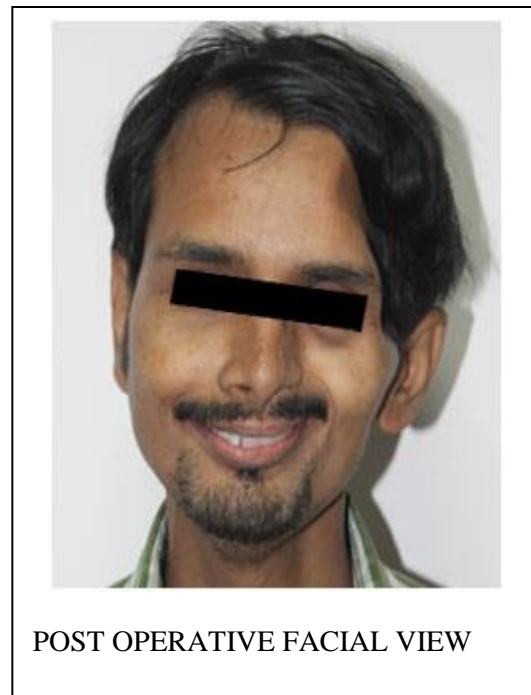
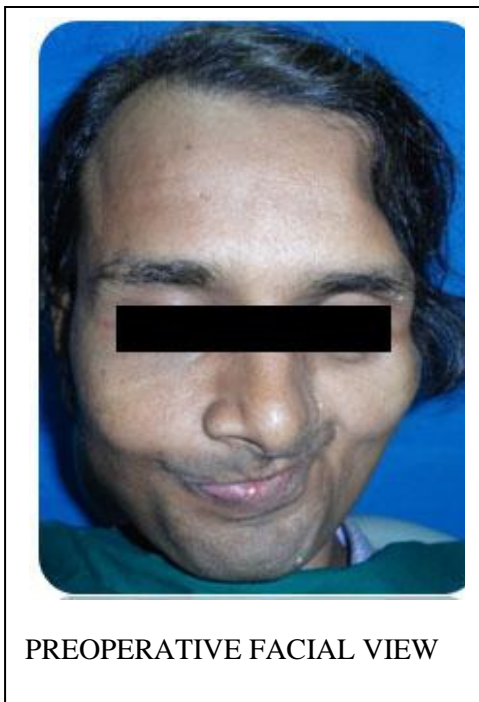
Maxillomandibular interocclusal record was registered. Wax try-in was done. Denture processed using heat cure acrylic resin. Denture portion and the bulb portion of the obturator were fused into single prosthesis.





After insertion of the prosthesis, patient's speech was examined. Patient was comfortable with no leakage of air during speech and no nasal regurgitation of fluids. Denture was found to be stable and retentive which might be due to engagement of bulb in the anatomic undercut and retentive clasps on the other side.



III. Discussion

Maxillary defects are created by surgical treatment of benign or malignant neoplasms, congenital malformation and by trauma. The size and location of the defects influence the degree of impairment and difficulty in prosthetic rehabilitation. Lack of support, retention, and stability are common prosthodontic treatment problems for patients who have had a maxillectomy. The obturator prosthesis is used to restore masticatory function and improve speech, deglutition and cosmetics for maxillary defect patients.

The primary goal of prosthetic rehabilitation is closure of the maxillectomy defect and separation of the oral cavity from the sinonasal cavities. A seal of the obturator bulb against the mucosal lining restores speech and swallowing functions. A successful designing of the prosthesis to restore function of the maxillectomy defect, utilizes the remaining palate and dentition to improve the support, stability and retention of the obturator. Armany's classification system reported in 1978 is referred frequently in the prosthodontic literature¹⁰. It addresses removable partial framework design and prosthetic

rehabilitation of the partially edentulous maxillectomy patient in 6 categories, in which this case comes under class 4 defect.

The problem faced by the patient is the heaviness of the prosthesis. There are ways to reduce the weight of the prosthesis; either the bulb portion of the obturator is generally processed hollow and/or the titanium alloy (low density) denture base framework¹¹. Weight reduction is especially important when the obturator prosthesis is suspended without bony or posterior tooth support on the defect side, as in the present case.

The retention of large obturator can be difficult, especially if they are solid and heavy, rather than hollow and light. In this case, we increase the retention by extending the lateral border of the prosthesis as high into the defect as possible to minimize the vertical displacement under load. We fabricated a two piece obturator with a maxillary plate and a bulb component. The hollow bulb extended into the undercut areas of the defect and enhanced the facial contour and retention. It facilitated easy examination of the underlying tissues and reestablished the anatomic barrier between the oral and nasal cavities and restored function and esthetics. Thus, it improved the quality of life, restored the masticatory function, improved speech, deglutition, prevented regurgitation of fluids and enhanced esthetics for the patient.

The other advantage of titanium framework is it significantly reduces the risk of infections with pathogenic oral microorganisms, may protect from local oral or systemic infections⁶.

IV. Conclusion

The maxillectomy patient who had functional deficiency with ill fitting single piece acrylic obturator, was very much comfortable with the titanium fully extended hollow bulb obturator, who regained the lost functions. Hollow bulb of the prosthesis reduced 33% the weight of the obturator and titanium plate reduced 13% of the weight of the prosthesis⁷. Approximately 46% weight reduction could be achieved. The reduced microbial adherence on the titanium framework, added to the benefit of decreased weight of the prosthesis.

References

- [1]. Understandability of Speech Predicts, Quality of Life Among Maxillectomy Patients
- [2]. Restored With Obturator Prosthesis, Crystianne Pacheco Seignemartin, DDS,* Milton E. Miranda, DDS, MS, PhD, Jo~ao Gualberto C. Luz, DDS, MS, PhD,^z and Rubens G. Teixeira, DDS, MS, PhD, American Association of oral and maxillofacial surgeons, *J Oral Maxillofacial surg* 73:2040-2048, 2015
- [3]. Cast titanium for obturator framework construction in maxilla facial prosthodontics, Bourne GK, Barber AJ, Wilson PH, *Eur J Prosthodont Restor Dent*. 2015 Dec;23(4):213-8
- [4]. Rehabilitation of large maxillary defect with two-piece maxillary obturators. Dholam KP, sadashiva KM, Bhirangi PP. *J Cancer Res Ther* 2015 Jul-sep;11(3):664.
- [5]. Two-piece hollow bulb obturator. Elangovan S¹, Loibi E. *Indian J Dent Res*. 2011 May-Jun;22(3):486-8.
- [6]. *Clinical Maxillofacial Prosthetics*, Taylor, Thomas D.
- [7]. Comparison of prevalence of microorganisms on titanium and silicone/polymethyl methacrylate obturators used for rehabilitation of maxillary defects. Rita S. Depprich et al. *J Prosthet Dent* vol 99, issue 5 , pg 400-405, may 2008
- [8]. A titanium and visible light polymerized resin obturator, Benito Rilo et al, *J prosthet Dent* 2002: 87:407-9.
- [9]. Prosthodontic guidelines for surgical reconstruction of the maxilla—a classification system of defects, Devin J. Okay, DDS,^a Eric Genden, MD,^b Daniel Buchbinder, DMD, MD,^c and Mark Urken, MD^d The Mount Sinai Medical Center, New York, N.Y. (*J Prosthet Dent* 2001;86:352-63.)
- [10]. Comparison of weight reduction in different designs of solid and hollow obturator prosthesis. – *Journal of prosthetic dentistry* 62(2): 21-7, AUG 1989
- [11]. Basic principles of obturator design for partially edentulous patients: design principles – Mohammed armany, *J Prosthet dent* vol 40: issue 6, dec 1978, 656-662
- [12]. Obturator prosthesis design for acquired maxillary defects – Ronald p. Desjardins, *J prosthet dent* vol 39, issue 4, apr 1978, pg 424-435.